



PATIENT

Ruby Adelman

SPECIES

Canine

BREED

Chi Mix

SEX

FS

AGE

12

WEIGHT

15.8

INTERPRETED BY

R. McKenzie Daniel,
DVM, DABVP
(Canine and Feline)

IMAGING PERFORMED BY

Jenn

HOSPITAL NAME

Rockaway Animal
Hospital

REFERRING VET

Dr Maniar

INVOICE 24278

DATE
03/24/2026

PRESENTING CLINICAL SIGNS

re check prev u/s 12/16 Owner reports doing well

ULTRASONOGRAPHIC EXAMINATION OF THE ABDOMEN

Urinary System

The urinary bladder, trigone, cystourethral junction, and visible pelvic urethra to a depth of 2 cm exhibited normal thickness and tone. Anechoic urine was present in the lumen with no evidence of urine/lumen sediment, mineral, or calculi. The ureteral papillae were normal. The ureters were not visible which is normal. No evidence of inflammatory or neoplastic changes was noted.

Normal size and margination were present in the kidneys. A normal 1:3 cortex / medulla ratio was maintained. The medulla and cortices were uniform in texture with some increased echogenicity and mild loss of corticomedullary symmetry and definition expected for the age of the patient. No evidence of pelvic dilation was present. Bilateral areas of pinpoint medullary mineral were present. The left kidney measured 3.9 cm in length. The right kidney measured 3.9 cm in length.

The area of the aortic trifurcation was free of pathology.

Adrenal Glands

The left adrenal gland was uniform in size and contour with a uniformly hypoechoic parenchyma. The left adrenal gland measured 0.45 cm width at the caudal pole. The right adrenal gland was uniform in size and contour with a uniformly hypoechoic parenchyma. The right adrenal gland measured 0.45 cm width at the caudal pole.

Spleen

The spleen exhibited a finely textured and homogenous parenchyma which was hyperechoic to the liver and renal cortical parenchyma. The capsule was smooth and regular without apparent expansion. The splenic vasculature at the hilus was normal in volume with no evidence of congestion or thrombosis. Acute to chronic inflammatory, neoplastic, or benign parenchyma changes were not noted.

Liver/Gallbladder

The liver presented mildly enlarged in size. The parenchyma of the liver was subjectively normal in echogenicity compared to the spleen and renal cortices. The liver parenchyma was uniform with a mildly coarse echotexture. The capsule of the liver was symmetrically rounded to mildly swollen in margination. The hepatic and portal vasculature were normal in appearance without signs of congestion. The gallbladder was non-distended in size with mild non-organized debris. The cystic and common bile ducts were normal.

Gastrointestinal

The stomach presented persistent subjective overall static thickened gastric wall, exhibiting significant to variable thickened gastric mucosa with non-homogenous mucosa echogenicity and potential focal cystic mucosa changes. Thickened ventral gastric body wall measured ~ 2.0-2.1 cm width. The stomach lumen was primarily empty with mild lumen gas and mild non-shadowing pyloric chyme. By comparison, the pylorus wall was intact and overall non-thickened without obstruction to pyloric outflow, measuring 0.33 cm wall width.



PATIENT

Ruby Adelman

The small intestine presented intact wall layering with 1:3 muscularis/mucosa ratio. The lumen of the small intestine was empty with no signs of mechanical/metabolic ileus, obstruction or foreign material.

Normal visible colon wall layers were present with apparent formed feces in lumen.

SPECIES

Canine

Pancreas

The parenchyma of the left limb, body and right limb of the pancreas presented isoechoic to the adjacent omental fat. A normal curvilinear capsule contour of the pancreas was present. The visible pancreatic duct was normal. No signs of active inflammation or neoplastic disease was evident.

BREED

Chi Mix

Free Abdomen

No omental masses, overt lymphadenopathy or peritoneal effusion was present.

SEX

FS

ULTRASONOGRAPHIC FINDINGS

Primary

- Static to similar appearing significant thickened gastric wall owing to non-homogenous possibly cystic thickened gastric mucosa
- Benign hepatomegaly with static non-organized gallbladder debris (non-mucocele)
- Sonographically normal empty small intestine
- Static mild chronic renal changes

AGE

12

WEIGHT

15.8

INTERPRETATION OF THE FINDINGS & FURTHER RECOMMENDATIONS

Similar subjective non-progressive yet significant thickened stomach wall compared to the previous study. Significant to chronic gastritis is favored in conjunction with overall similar sonographic presentation and previous gastric biopsy results. Potential for gastric neoplasia, infectious disease or other is not definitively excluded. Given current clinical presentation, continued empirical therapy for gastritis with as needed sonographic reassessment would be reasonable.

INTERPRETED BY

R. McKenzie Daniel,
DVM, DABVP
(Canine and Feline)

IMAGING PERFORMED BY

Jenn

HOSPITAL NAME

Rockaway Animal
Hospital

REFERRING VET

Dr Maniar

INVOICE

24278

DATE

03/24/2026



PATIENT

Ruby Adelman

SPECIES

Canine

BREED

Chi Mix

SEX

FS

AGE

12

WEIGHT

15.8

INTERPRETED BY

R. McKenzie Daniel,
DVM, DABVP
(Canine and Feline)

IMAGING PERFORMED BY

Jenn

HOSPITAL NAME

Rockaway Animal
Hospital

REFERRING VET

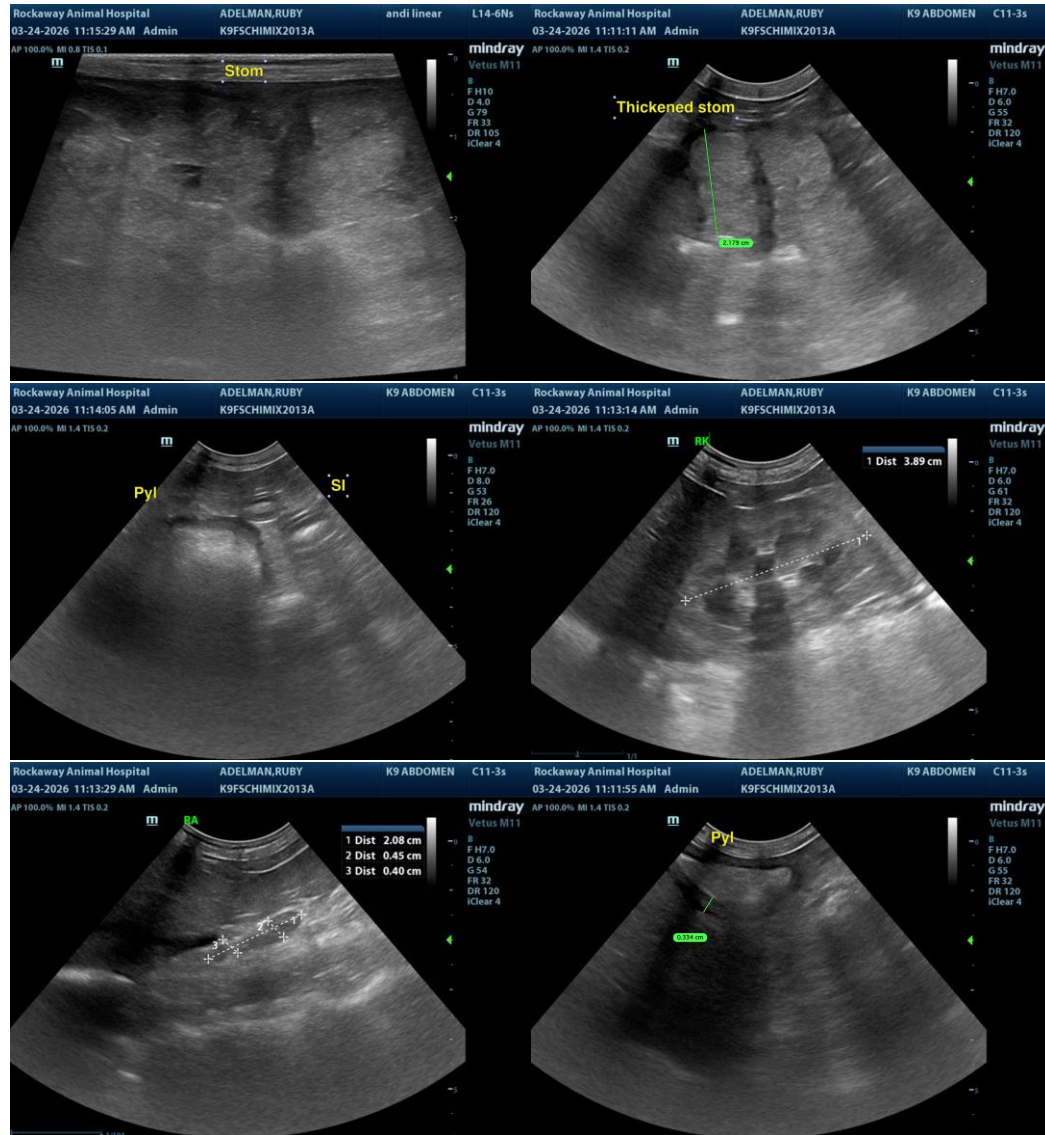
Dr Maniar

INVOICE

24278

DATE

03/24/2026





PATIENT

Ruby Adelman

SPECIES

Canine

BREED

Chi Mix

SEX

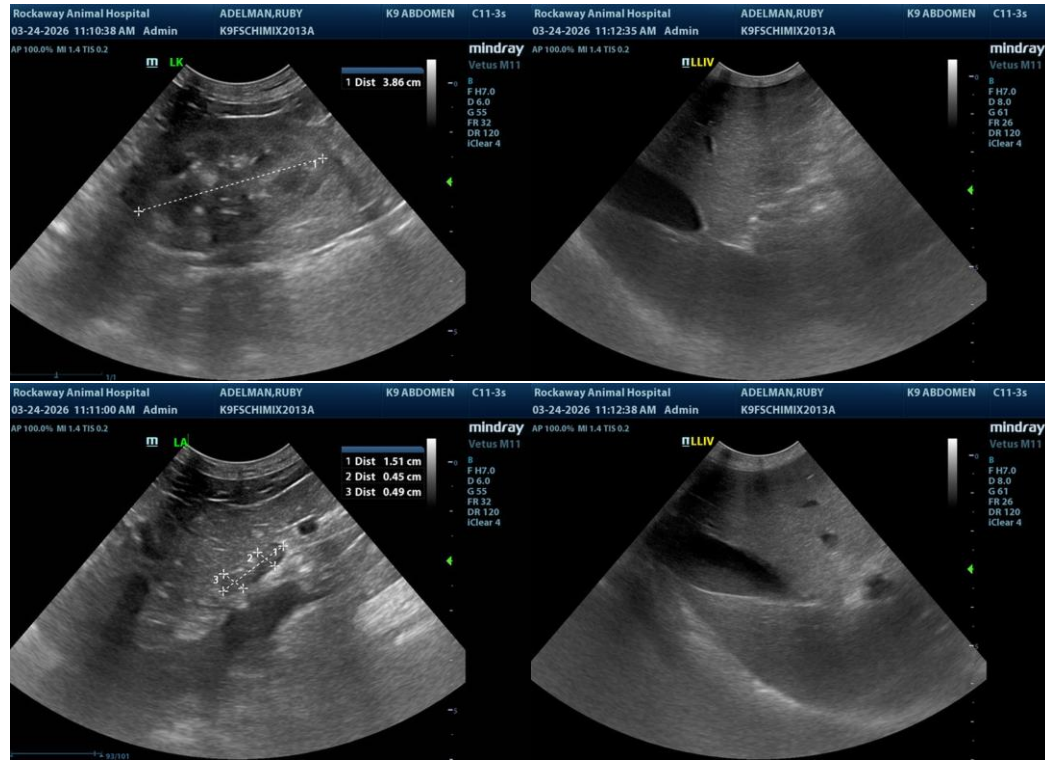
FS

AGE

12

WEIGHT

15.8



INTERPRETED BY

R. McKenzie Daniel,
DVM, DABVP
(Canine and Feline)

The information and recommendations provided are based on the images presented by the referring veterinarian/sonographer. No evaluation can be communicated regarding pathology that was not visible in the image/video clips provided.

Thank you for this referral. If the clinical or image interpretation does not parallel your findings or if I can be of any further assistance, please contact me.

IMAGING PERFORMED BY

Jenn

R. McKenzie Daniel, DVM, DABVP (Canine/Feline Practice)
info@sonopath.com

HOSPITAL NAME

Rockaway Animal
Hospital

REFERRING VET

Dr Maniar

INVOICE

24278

DATE

03/24/2026